BRAIN INJURY

http://informahealthcare.com/bij
ISSN: 0269-9052 (print), 1362-301X (electronic)

Brain Inj, Early Online: 1–4
 DOI: 10.3109/02699052.2014.890745

informa healthcare

CASE STUDY

Functional neuroimaging of personally-relevant stimuli in a paediatric case of impaired awareness

Christopher R. Nicholas[1,2], Donald G. McLaren[3,4,5], Michael J. Gawrysiak[6], Baxter P. Rogers[7,8], John H. Dougherty[9], & Michael R. Nash[10]

[1]Geriatric Research Education and Clinical Center (GRECC), William S. Middleton Memorial Veterans Hospital, Madison, WI, USA, [2]University of Wisconsin School of Medicine and Public Health, Madison, WI, USA, [3]GRECC, ENRM VA Medical Center, Bedford, MA, USA, [4]Department of Neurology, Massachusetts General Hospital, Boston, MA, USA, [5]Harvard Medical School, Boston, MA, USA, [6]Mental Illness Research, Education, and Clinical Center (MIRECC), Philadelphia Veterans Medical Center, Philadelphia, PA, USA, [7]Vanderbilt University Institute of Imaging Science, Nashville, TN, USA, [8]Department of Radiology and Radiological Sciences, Vanderbilt School of Medicine, Nashville, TN, USA, [9]Cole Neuroscience Center, University of Tennessee Medical Center, Knoxville, TN, USA, and [10]Department of Psychology, University of Tennessee, Knoxville, TN, USA

Abstract

Background: Functional neuroimaging studies have observed preserved neural activation to personally relevant stimuli in patients within the disorders of consciousness (DOC) spectrum. As the majority of studies have focused on adult DOC patients, little is known about preserved activation in the developing brain of children with impaired consciousness.
Case study: The aim of this study is to use fMRI to measure preserved neural activation to personally relevant stimuli (subject's own name and familiar voice) in a paediatric patient who sustained a traumatic brain injury and anoxic-ischaemia following a motor vehicle accident at 18 months of age rendering her probable for minimally conscious state. Contrasts revealed activation in the right middle frontal gyrus when hearing the subject's own name and the anterior supramarginal gyrus when hearing a familiar voice.
Conclusion: This study provides preliminary support for fMRI as a method to measure preserved cognitive functioning in paediatric DOC patients.

Keywords

Brain imaging, brain injury, cognition, consciousness, paediatric, neurology, self-referential

History

Received 15 August 2013
Revised 29 November 2013
Accepted 28 January 2014
Published online 13 March 2014

Introduction

In recent years, functional neuroimaging has become a complementary method to bedside evaluation of preserved cognitive function in unresponsive brain damaged patients within the disorders of consciousness (DOC) spectrum. Some DOC patients show neural activation to personally relevant and meaningful auditory language stimuli such as hearing one's own name or a familiar voice [1–7]. Although there is uncertainty regarding the automaticity of these neural responses, current research suggests that at least some residual higher-level cortical processing may be intact. As the majority of functional neuroimaging studies have focused on adult DOC patients, little is known about the quality and extent of residual processing in the developing brain of children with impaired consciousness. Therefore, the aim of this study is to use functional magnetic resonance imaging (fMRI) to determine if there is preserved neural activation to personally relevant, potentially meaningful stimuli, in a paediatric DOC patient who is non-communicative and displays minimal behavioural signs of awareness of self and others.

Correspondence: Christopher R. Nicholas, Alzheimer's Disease Research Center, University of Wisconsin, 600 Highland Drive, Madison, WI 53792, USA. E-mail: psynich@gmail.com

Case study

Patient characteristics

A 7-year-old female DOC patient was recruited through the University of Tennessee Medical Center Department of Neurology. At 18-months of age the patient sustained a C1–C2 cervical fracture, traumatic brain injury (Glasgow Coma Scale = 4) [8] and anoxic-ischaemia following a motor vehicle accident (MVA), rendering her non-communicative, quadriplegic and ventilator dependent. Prior to the MVA, the patient was healthy and met normal developmental milestones. Initial MRI of the brain following her injury indicated bilateral basal ganglia lesions. An MRI 1-year prior to the patient's participation in the study revealed scarring from these lesions, with the rest of the brain being unremarkable; showing a normal size ventricular system and sulci, normal brainstem and cerebellum and no evidence of a mass lesion or mass effect. In addition, auditory evoked potentials of the brainstem produced a normal waveform amplitude and configuration. Assessment with the Coma Recovery Scale-Revised (CRS-R) [9] prior to the fMRI scan revealed a

probable diagnosis of minimally conscious state (MCS). Specifically, the patient was positive for being awake without stimulation, displaying oral reflexive movement and sustained visual tracking to light/mirror stimuli; and negative for an auditory startle response, following commands, intelligible verbalizations and motor response (unclear due to quadriplegia).

Experimental design

The patient listened to several variants of the phrase (e.g. 'Allison, hello Allison') through MRI-compatible noise-attenuating headphones, with each phrase presented in an event-related fashion [5]. The auditory stimuli included the subject's own name spoken by a familiar voice (own/familiar); subject's own name spoken by unfamiliar voices (own/unfamiliar); other names spoken by a familiar voice (other/familiar); and other names spoken by unfamiliar voices (other/unfamiliar). The familiar voice was the patient's mother and the unfamiliar voices were spoken by women who did not know the patient. Other names were matched to the gender and number of syllables of the subject's own name and unfamiliar voices were matched to the regional accent of the patient's mother. Eight fMRI runs were conducted where each contained 25 repetitions of each trial type (trial duration = 2000 milliseconds, average inter-trial interval = 1750 milliseconds). The patient was awake with eyes open during the study and required artificial ventilation with a MRI-compatible ventilator. The anaesthesiologist monitored the patient's wakefulness throughout the scan.

Imaging

Magnetic resonance imaging was performed on a 1.5 Tesla Siemens MRI scanner with a standard single channel head coil. Functional blood-oxygen level-dependent (BOLD) images were collected with the following T2*-weighted echo planar protocol: repetition time (TR) = 2500 milliseconds; echo time (TE) = 50 milliseconds; matrix = 64 × 64; field of view (FOV) = 192 × 192 mm, flip angle = 90°, voxel size = 3 × 3 × 3.8 mm and 27 sagittal slices with a thickness of 3 mm and a 0.75 mm gap. In each run, 150 images were acquired. Prior to the functional scans, a whole-brain anatomical T2-half-fourier acquisition single-shot turbo spin-echo (HASTE) image was acquired for functional registration and localization: TR = 1000 milliseconds; TE = 86 milliseconds; matrix = 512 × 512; FOV = 196 × 196 mm; flip angle = 90°; voxel size = 0.383 × 0.383 × 3.75 and 27 axial slices that were 3 mm thick with a 0.75 mm gap.

Image analysis

Images were motion corrected to the first functional image with masking to remove the influence of signal dropout in the left occipital lobe due to a pre-existing metal rod at the C1–C3 dissection site using the Art Repair Toolbox (Center for Interdisciplinary Brain Science Research, Stanford University, Palo Alto, CA) in Statistical Parametric Mapping (SPM8; Wellcome Department of Cognitive Neurology, London, UK). Additionally, the high-resolution T2-weighted anatomical image was co-registered to the functional images to provide an underlay for viewing the results.

This study used a general linear model to derive BOLD activations for each of the four conditions. Briefly, each condition (own/familiar, own/unfamiliar, other/familiar and other/unfamiliar) was convolved with a canonical haemodynamic response function to form task regressors. Additionally, the GLMs included a constant term per run, a high pass filter (cut-off = 1/260 Hz), AR1 autoregressive function and motion parameters. Contrasts were then performed using *t*-tests to determine differential brain activation between all auditory stimuli vs baseline, own-other names, familiar-unfamiliar voices, own/familiar-own/unfamiliar, other/familiar-other/unfamiliar, own/familiar-other/familiar and own/unfamiliar-other/unfamiliar. To deal with the problem of multiple comparisons, an uncorrected p-value of 0.001 was applied at each voxel. Clusters with a corrected and/or uncorrected cluster size threshold of $p < 0.05$ were then retained at the whole brain level and an extent threshold of eight contiguous voxels was used. Given the unique medical status of this patient and the overall exploratory nature of this study, we attempted to achieve a balance between Type I and Type II error rates by also reporting uncorrected significant results. Because of severe movement artifacts, only the first two functional runs were included. Nevertheless, the 50 stimuli of each trial type should be sufficient for an fMRI case study [10].

Results

The all auditory stimuli > baseline contrast revealed activation in the anterior cingulate gyrus ($p = 0.04$ cluster uncorrected threshold) as well as a substantial region spanning the left superior and transverse temporal gyrus ($p = 0.02$ cluster corrected; primary auditory cortex) spreading into ventral region of Wernicke's area and Heschle's gyrus (Figure 1, Table I). The reverse contrast, baseline > all auditory stimuli, revealed a region of activation in the post-central gyrus ($p = 0.007$ cluster corrected; somatosensory cortex) during baseline.

The contrast own > other revealed significant activation in the right middle frontal gyrus ($p = 0.04$ cluster uncorrected). The reverse contrast, other > own, revealed significant activation in the right middle temporal gyrus ($p = 0.009$ cluster corrected).

The contrast familiar > unfamiliar revealed significant activation in a large region of the anterior supramarginal gyrus ($p = 0.04$ cluster corrected; Figure 1, Table I). The reverse contrast, unfamiliar > familiar, did not reveal any significant activation. The contrasts, own/familiar–own/unfamiliar, other/familiar–other/unfamiliar, own/familiar–other/familiar and own/unfamiliar–other/unfamiliar did not reveal any significant activation.

Discussion

To the best of the authors' knowledge, this is the first fMRI study to measure preserved cognitive functioning in a paediatric DOC patient. For this reason, one is, for the most part, limited to comparing these results with those of studies using healthy subjects and adult DOC patients.

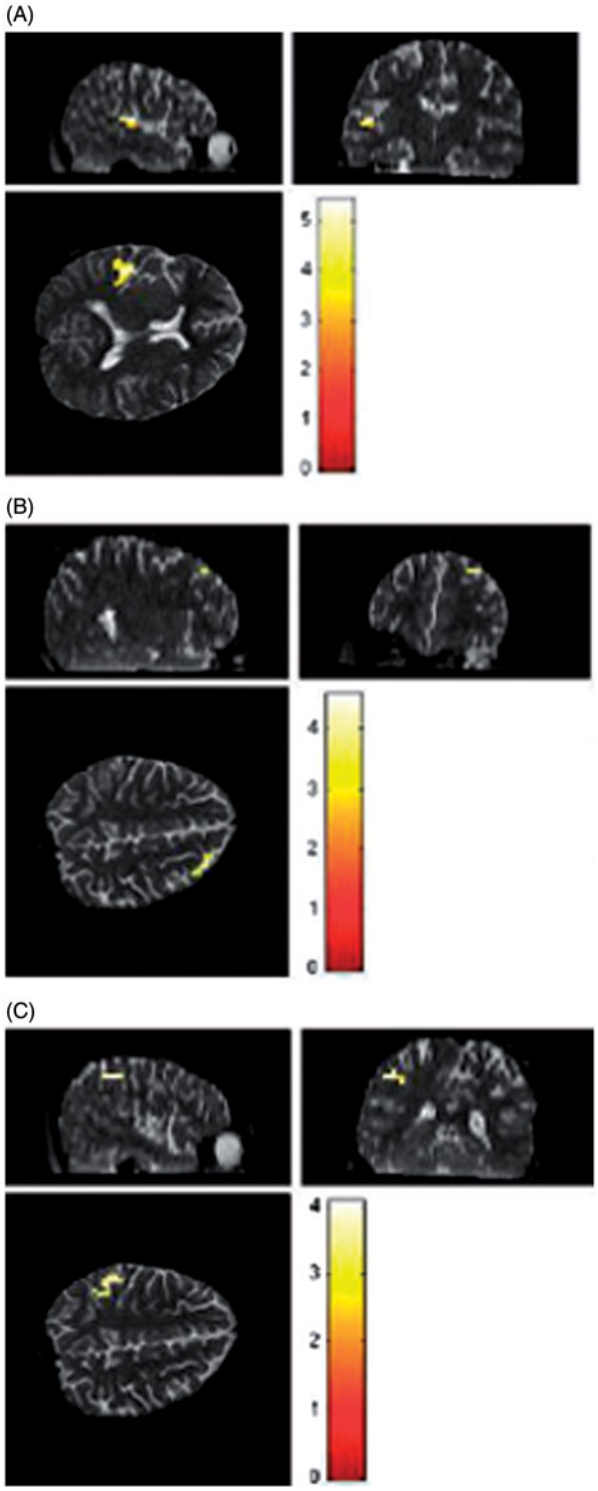

Figure 1. Areas of activation projected on patient's T2-HASTE anatomical image. (a) Activation of the left superior and transverse temporal gyri and anterior cingulate gyrus produced by the silent baseline (no stimuli) subtracted from all auditory language stimuli. (b) Activation of the right middle frontal gyrus produced from other names subtracted from the subject's own name. (c) Activation of the left anterior supramarginal gyrus produced by unfamiliar voices subtracted from the subject's mother's voice.

When collapsing across all auditory stimuli, compared to baseline, a robust left lateralized activation was found in the primary auditory cortex, an area commonly observed during auditory language processing tasks in healthy subjects and some DOC patients [2, 11–14]. Presentation of the subject's own name (own name > other name) was inconsistent with studies of adult DOC [5] and healthy subjects [15], who found activation in cortical midline structures, a network of regions proposed to play a key role in processing self-related stimuli [16]. Instead, at an uncorrected threshold, activation was found in the right middle frontal gyrus (MFG) within the dorsolateral prefrontal cortex (DLPFC), an area believed to be involved in making evaluations about the self [17]. Consequently, it was speculated that the subject's own name was more salient [18] than hearing other names, as the reverse contrast (other names > own name) produced activation in the middle temporal gyrus, a region commonly associated with basic and possibly more neutral language processing in children [11, 19].

Table I. Brain activation during auditory stimuli.

Brain areas	Side	Voxels	*p* (corr)	*p* (uncorr)
All auditory stimuli > Baseline				
Superior & Transverse Temporal Gyri	L	24	0.021	0.001
Anterior Cingulate Gyrus	L	8	0.455	0.043
Baseline > All auditory stimuli				
Post-central Gyrus	L	16	0.096	0.007
Own name > Unknown name				
Middle Frontal Gyrus	R	8	0.474	0.043
Unknown name > Own name				
Middle Temporal Gyrus	R	29	0.009	0.001
Familiar voice > Unfamiliar voice				
Anterior Supramarginal Gyrus	L	21	0.037	0.002
Unfamiliar voice > Familiar voice				
No clusters of activation*				

* no significant voxels at $p < 0.005$.

The finding of left lateralized SMG activation during the presentation of a familiar voice relative to unfamiliar voices is inconsistent with similar studies involving DOC patients [1, 20]. These studies observed robust amygdala activation, suggesting an emotional response to a family member's voice. However, the lack of activation to unfamiliar voices in this patient may suggest a greater orienting/attentional response to the familiar voice as the SMG is involved in higher-level language processing [21]. This would be partially consistent with Machado et al. [4, 22], who studied an 8-year-old PVS patient that showed a significant left lateralized EEG response and increased parasympathetic activation to a familiar voice, but no response to unfamiliar voices.

While differences in methodology and patient characteristics make it challenging to derive inferences from other studies about this patient's neurocognitive course and status, it was cautiously speculated that her injuries at 18 months of age may have impeded the transactional relationship [23] between the natural course of brain maturation and exposure to enriching environmental factors that together contribute to the development of basic cognitive representational abilities typically observed in 7-year-old children (e.g. meta-cognition, self-recognition, personal pronoun use, self-conscious emotions, imitation, theory of mind). Thus, one limitation of these results is that it remains unclear if her brain activation patterns are to be considered in terms of her chronological age or of an aberrant developmental time point. In addition,

neurodevelopmental differences between children and adults, particularly within the frontal lobes, make it difficult to compare these results with studies involving adult subjects. Including an age-matched control sample may have shed light on the patient's neurocognitive capacity to represent the self and others, particularly since there was no evidence of volumetric abnormalities in corresponding brain regions.

There are a couple additional important limitations of this study inherent to investigating DOC patients with functional neuroimaging. First, because this study was unable to obtain a direct behavioural measurement of self and other awareness, this patient's level of conscious processing of personally relevant stimuli is still unknown. Second, the presence of motion artifact prevented the inclusion of the last six functional runs into the analyses. The probability of detecting a significant effect across voxels would have likely been increased, thus possibly negating the use of an uncorrected cluster *p*-value for some contrasts. As this is a case study of DOC, it was felt that increasing the false positive error rate was acceptable as it decreases the false negative error rate.

While this study cannot directly inform aetiological and diagnostic aspects of this patient's impairments, the patient did evidence partially preserved brain activation patterns consistent with adult subjects. This study supports the use of fMRI as a method to measure preserved cognitive functioning in paediatric DOC patients and provides a foundation for future studies investigating the effects of severe brain trauma on brain maturation and development.

Acknowledgements

Special thanks to the Cole family and to the Cole Neuroscience Center at the University of Tennessee Medical Center. The authors thank Russell Langdon, MD for his assistance with the patient's mechanical ventilation during the fMRI scan. The content is solely the responsibility of the authors and does not represent the official views of the United States Government, Department of Veterans Affairs, National Institutes of Health, or National Institute of Aging.

Declaration of interest

This research would not have been possible without the generous financial support of the Cole Neuroscience Gift fund. The authors report no conflicts of interest.

References

1. Bekinschtein T, Niklison J, Sigman L, Manes F, Leiguarda R, Armony J, Owen A, Carpintiero S, Olmos L. Emotion processing in the minimally conscious state. Journal of Neurology, Neurosurgery & Psychiatry 2004;75:788.
2. Di HB, Yu SM, Weng XC, Laureys S, Yu D, Li JQ, Qin PM, Zhu YH, Zhang SZ, Chen YZ. Cerebral response to patient's own name in the vegetative and minimally conscious states. Neurology 2007;68:895–899.
3. Laureys S, Perrin F, Faymonville ME, Schnakers C, Boly M, Bartsch V, Majerus S, Moonen G, Maquet P. Cerebral processing in the minimally conscious state. Neurology 2004;63:916–918.
4. Machado C, Korein J, Aubert J, Bosch J, Alvarez MA, Rodriguez R, Valdés P, Portela L, García M, Pérez N, et al. Recognizing a mother's voice in the persistent vegetative state. Clinical EEG and Neuroscience Journal 2007;38:124–126.
5. Staffen W, Kronbichler M, Aichhorn M, Mair A, Ladurner G. Selective brain activity in response to one's own name in the persistent vegetative state. Journal of Neurology, Neurosurgery & Psychiatry 2006;77:1383–1384.
6. Crone JS, Höller Y, Bergmann J, Golaszewski S, Trinka E, Kronbichler M. Self-related processing and deactivation of cortical midline regions in disorders of consciousness. Frontiers in Human Neuroscience 2013;26:504.
7. Qin P, Di H, Liu Y, Yu S, Gong Q, Duncan N, Weng X, Laureys S, Northoff G. Anterior cingulate activity and the self in disorders of consciousness. Human Brain Mapping 2010;31:1993–2002.
8. Teasdale G, Jennett B. Assessment of coma and impaired consciousness. Lancet 1974;304:81–84.
9. Giacino JT, Kalmar K, Whyte J. The JFK Coma Recovery Scale-Revised: Measurement characteristics and diagnostic utility. Archives of Physical Medicine & Rehabilitation 2004;85: 2020–2029.
10. Huettel SA, McCarthy G. The effects of single-trial averaging upon the spatial extent of fMRI activation. Neuroreport 2001;12: 2411–2416.
11. Balsamo LM, Xu B, Grandin CB, Petrella JR, Braniecki SH, Elliott TK, Gaillard WD. A functional magnetic resonance imaging study of left hemisphere language dominance in children. Archives of Neurology 2000;59:1168–1174.
12. Binder JR, Rao SM, Hammeke TA, Frost JA, Bandettini PA, Jesmanowicz A, Hyde JS. Lateralized human brain language systems demonstrated by task subtraction functional magnetic resonance imaging. Archives of Neurology 1995;52:593–601.
13. Boly M, Faymonville ME, Peigneux P, Lambermont B, Damas P, Del Fiore G, Degueldre C, Franck G, Luxen A, Lamy M, et al. Auditory processing in severely brain injured patients: Differences between the minimally conscious state and the persistent vegetative state. Archives of Neurology 2004;61:233–238.
14. Laureys S, Faymonville ME, Degueldre C, Fiore GD, Damas P, Lambermont B, Janssens N, Aerts J, Franck G, Luxen A, et al. Auditory processing in the vegetative state. Brain 2000;123: 1589–1601.
15. Kampe KK, Frith CD, Frith U. 'Hey John': Signals conveying communicative intention toward the self activate brain regions associated with ''mentalizing,'' regardless of modality. Journal of Neuroscience 2003;23:5258–5263.
16. Northoff G, Heinzel A, de Greck M, Bermpohl F, Dobrowolny H, Panksepp J. Self-referential processing in our brain–A meta analysis of imaging studies on the self. Neuroimage 2006;31: 440–457.
17. Schmitz TW, Kawahara Baccus TN, Johnson SC. Metacognitive evaluation, self-relevance, and the right prefrontal cortex. Neuroimage 2004;22:941–947.
18. Laureys S, Perrin F, Brédart S. Self-consciousness in non-communicative patients. Consciousness and Cognition 2007;16: 722–741.
19. Ahmad Z, Balsamo LM, Sachs BC, Xu B, Gaillard WD. Auditory comprehension of language in young children: Neural networks identified with fMRI. Neurology 2003;60:1598–1605.
20. Eickhoff SB, Dafotakis M, Grefkes C, Stöcker T, Shah NJ, Schnitzler A, Zilles K, Siebler M. fMRI reveals cognitive and emotional processing in a long-term comatose patient. Experimental Neurology 2008;214:240–246.
21. Price CJ. The anatomy of language: A review of 100 fMRI studies published in 2009. Annals of the New York Academy of Science 2010;1191:62–88.
22. Machado C, Estévez, M, Gutiérrez, J, Beltrán C, Machado Y, Machado Y, Chinchilla M, Pérez-Nellar J. Recognition of the mom's voice with an emotional content in a PVS patient. Clinical Neurophysiology 2011;122:1059–1060.
23. Fox NA, Calkins SD, Bell MA. Neural plasticity and development in the first two years of life: Evidence from cognitive and socioemotional domains of research. Development and Psychopathology 1994;6:677–696.